

Alveolar ridge preservation in growing patient with dentoalveolar ankylosis

Case report with 4-year follow-up after decoronation



Battsetseg Tseveenjav^{1,2} & Heikki Alapulli¹

¹Department of Oral and Maxillofacial Diseases, Children's Hospital, Helsinki University and Helsinki University Hospital, Helsinki, Finland

²University of Turku, Turku, Finland



ANKYLOSIS

Dentoalveolar ankylosis is an anatomical fusion of tooth cementum with alveolar bone. In children, ankylosis is usually developed as consequence of severe dental trauma as tooth avulsion, intrusion, extrusion, or lateral luxation (Andreasen, 1981; Dental Trauma Guide, IADT, 2020).

Consequences of ankylosis are more serious in growing patients than in adults because the rate of the cementum replacement by bone is more rapid and eventually the affected tooth crown will fall off as it is deprived of root support. Sequela of ankylosis can range from a mild localized infra-position to a more severe form. In severe cases happen disturbances in both alveolar ridge and facial growth and tilting of adjacent teeth (Malmgren et al. 1984; Malmgren, 2013; Mohadeb et al., 2016).

Different intervention alternatives for the management of ankylosed permanent anterior teeth have been described, but effectiveness of the options is unclear due to a lack of reports of randomized controlled trials (De Souza et al., 2015). Malmgren et al. (1984), introduced decoronation, as treatment option, which involves a coronectomy of the ankylosed tooth beneath the level of the cementum-enamel-junction and instrumentation of the pulp canal to stimulate bleeding at the periapical area. Flapless decoronation is a modification of the classic decoronation, which can be used as a minimally invasively to simplify the procedure and facilitate healing process (Shay et al., 2022).

PATIENT REFERRAL

- A 11-year-old healthy boy was referred by orthodontist from primary health care to the Pediatric Dental Clinic of the New Children's Hospital of the Helsinki University Central Hospital, in Jan 2018
- Main complaint was maxillary right central incisor (tooth d. 11) in infra-position
- Dental history revealed, that at the age of 8, the tooth in question had avulsion (Figure 1)
- The tooth was replanted in an emergency visit (Figure 2) in September 2013

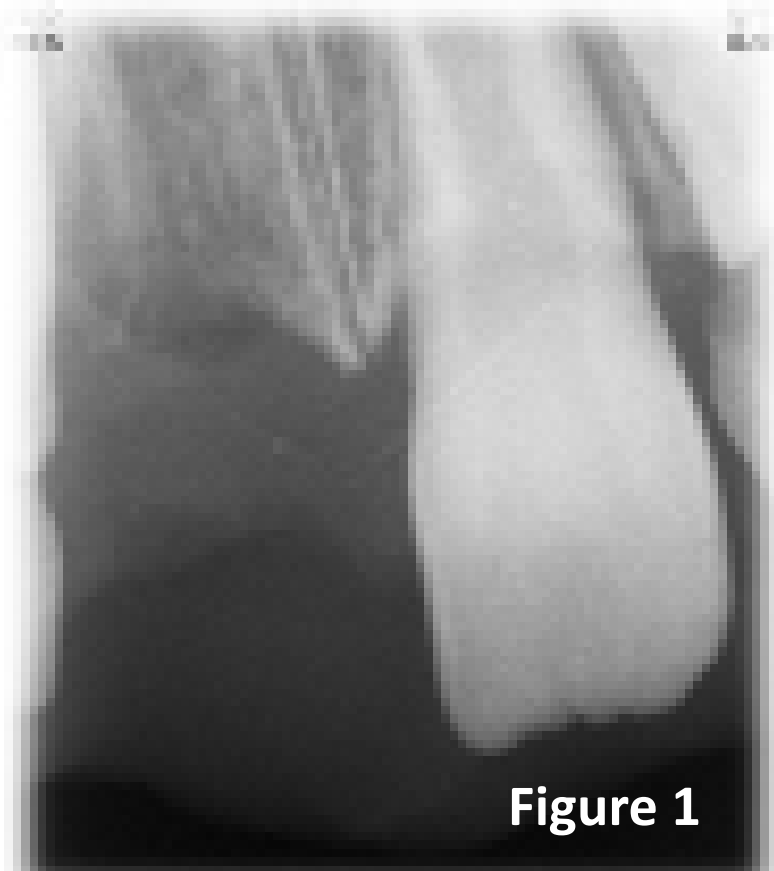


Figure 1

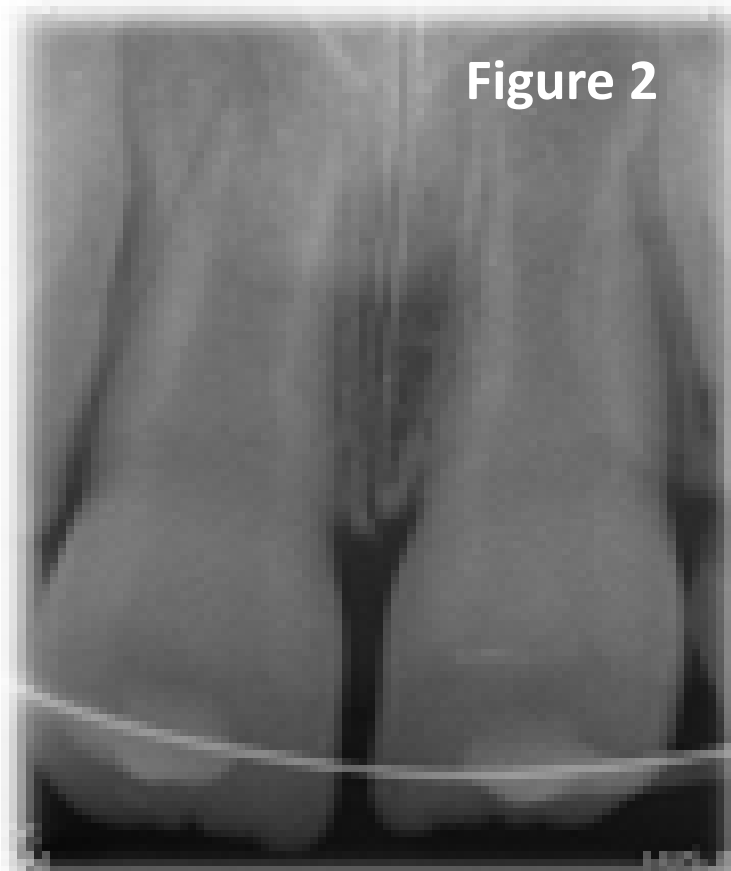


Figure 2

Intraoral X-rays of the emergency visit after the tooth d. 11:

- Figure 1: D. 11 avulsed
- Figure 2: D. 11 splinted

PRE-OPERATIVE VISIT

- Pre-operative visit at the Helsinki University Central Hospital, in March 2018
- Clinically (Figures 3 by BT):
 - Good oral hygiene and caries free
 - D. 11 in infra-position
 - No subjective symptoms
 - A metallic sound upon percussion
 - Moderate ankylosis

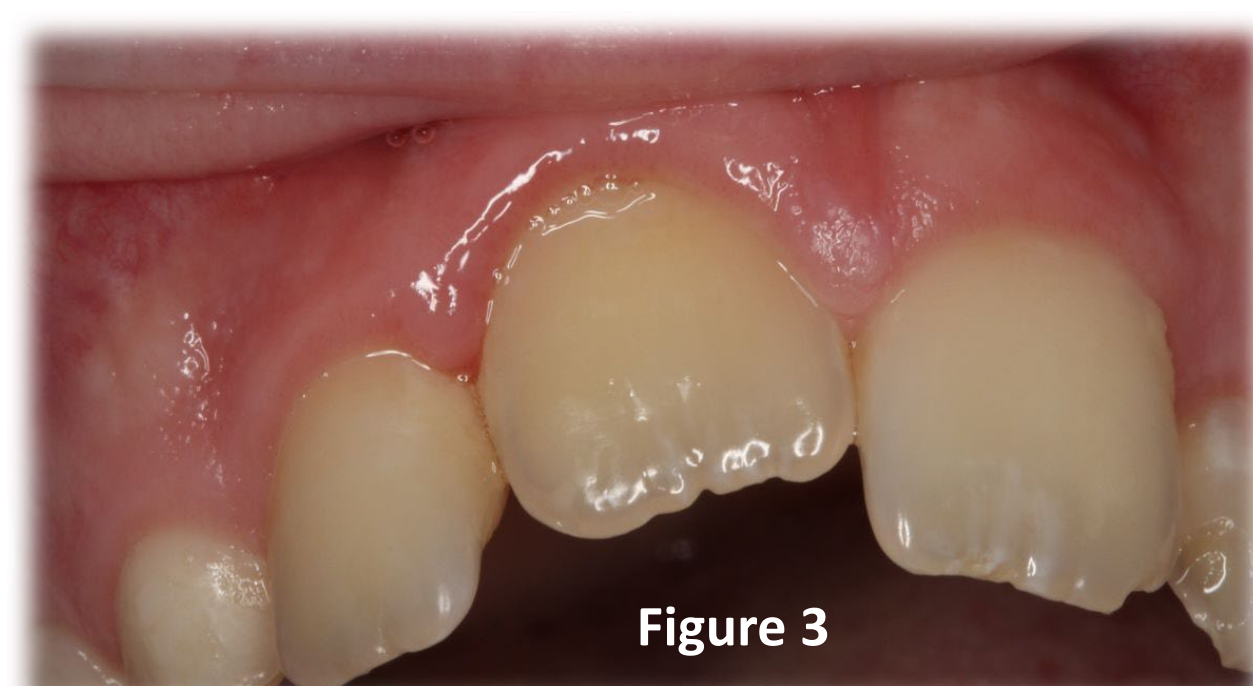

Figure 3

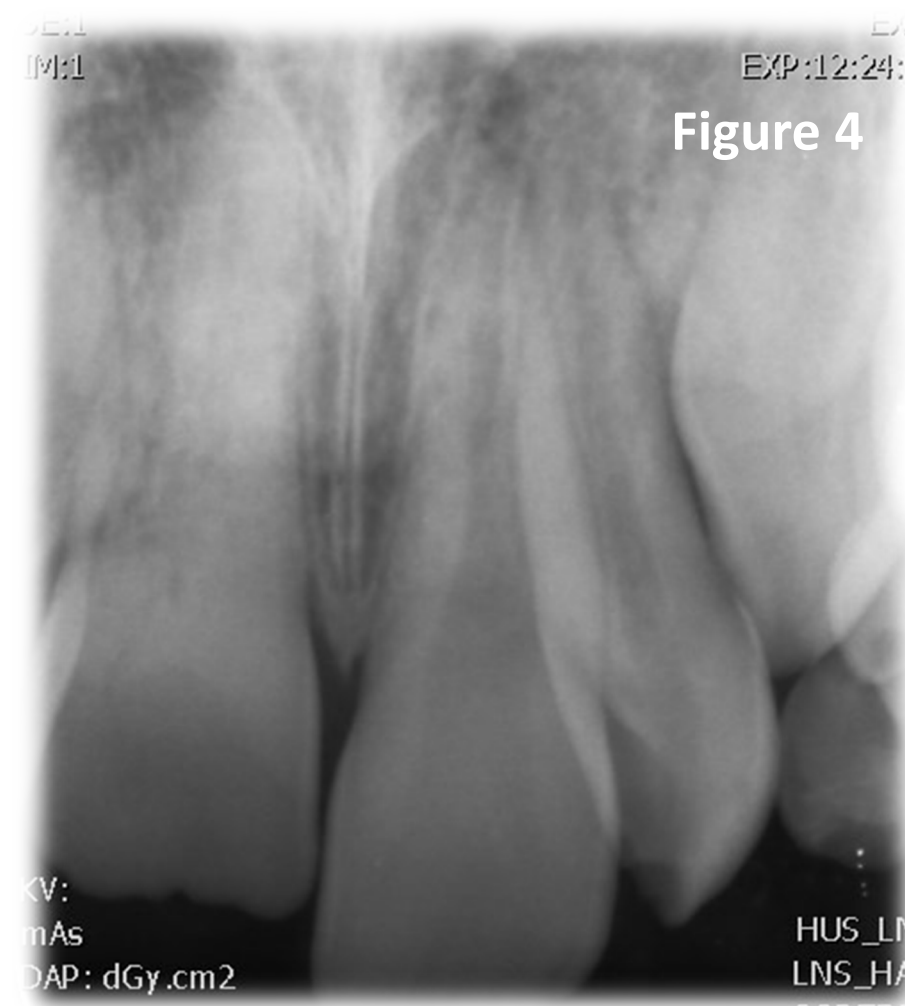


Figure 4

X-ray revealed:

- Absence of the periodontal ligament space (Figure 4 by BT)
- Pulp chamber obliteration
- No tilting in neighbouring teeth

DECORONATION PROCEDURE

Flapless decoronation procedure carried out in April 2018, by the authors, BT & HA. Under local anesthesia, without the raising of a full-thickness flap, the dental crown is removed using a diamond bur. The root is reduced by 1.5 mm apically to the marginal bone crest, taking particular care of no touching the bone. After removing the crown, a K-file was used to extract the content of from root canal, which was then washed with a saline solution, allowing the canal to fill with blood. Due to the obliteration, the bleeding was scarce. Wound closure was obtained by coronal repositioning of the soft tissue and by placement of absorbable sutures, making sure close adaptation to the surrounding soft tissue to prevent further infection. Post-operative instructions were given, and follow-up appointment was made.

POST-OPERATIVE CONTROL

Post-operative control was in May 2018. Patient recovered from the operation without any complication. The wound area was cleaned well. Clinical and radiographic examination was carried out at this visit (Figures 5). Replacement of decoronated tooth by temporary solution as well as the further follow-ups were planned to be carried out in primary health care center, where specialist in pediatric dentistry was available for consultation.

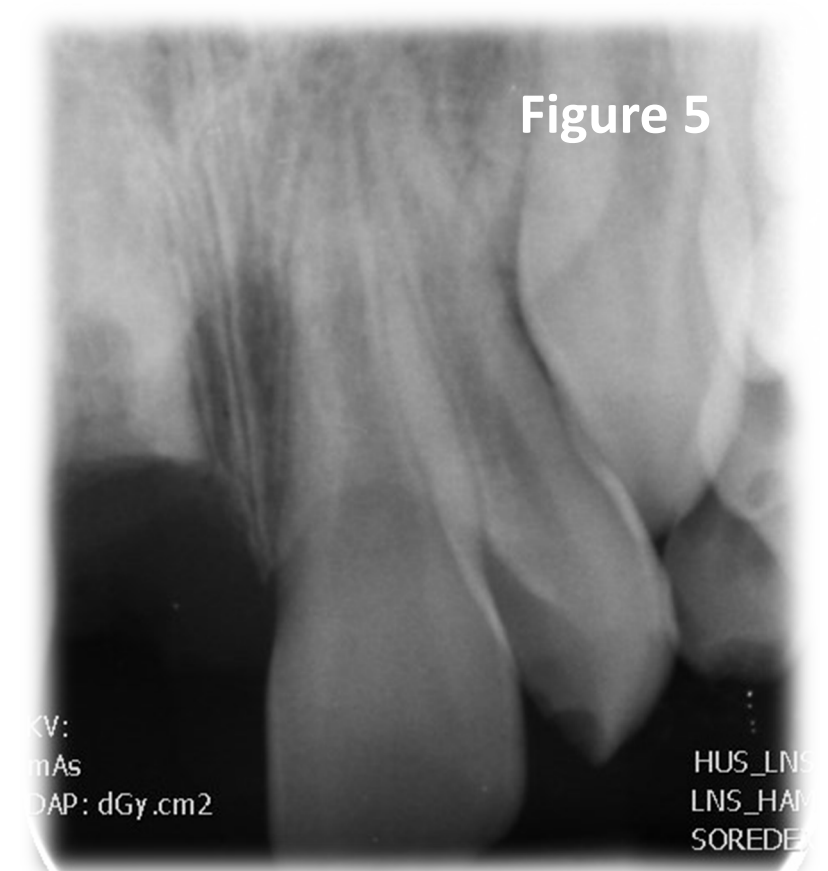


Figure 5

FOLLOW-UPS

The follow-up visits were in spring 2019, 2020 and 2022 (Figures 6a-c, respectively, by pediatric dentist Brander Eerika). In the 12-, 24- & 48-month follow-ups alveolar ridge showed vertical and horizontal growth of bone and continuing replacement of the root by bone. The region of decoronated d. 11 remained without any objective and subjective symptoms.

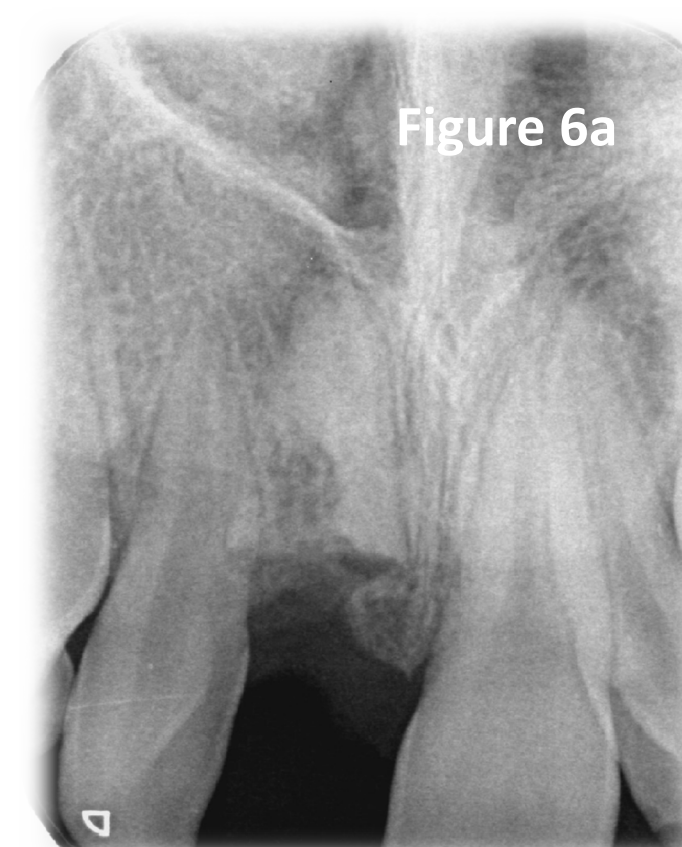

Figure 6a

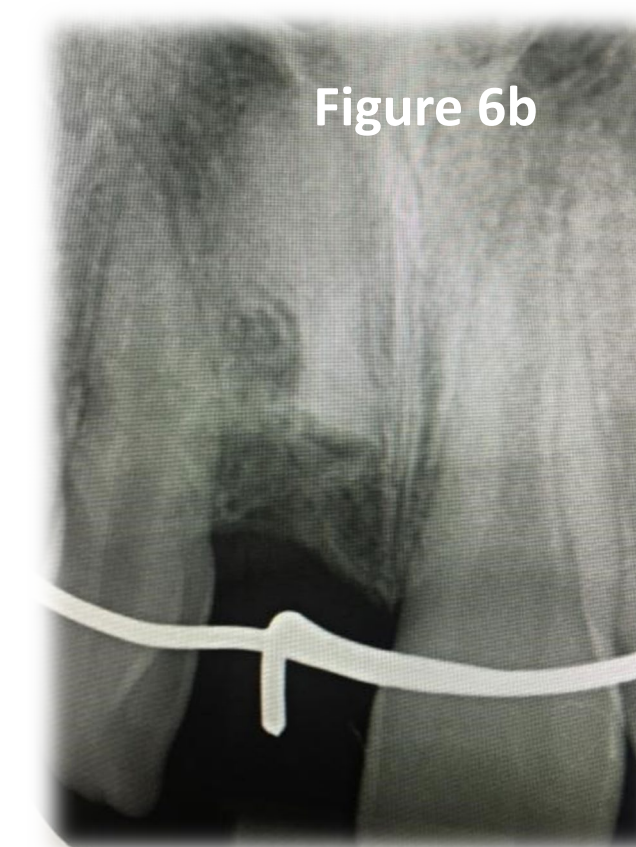


Figure 6b

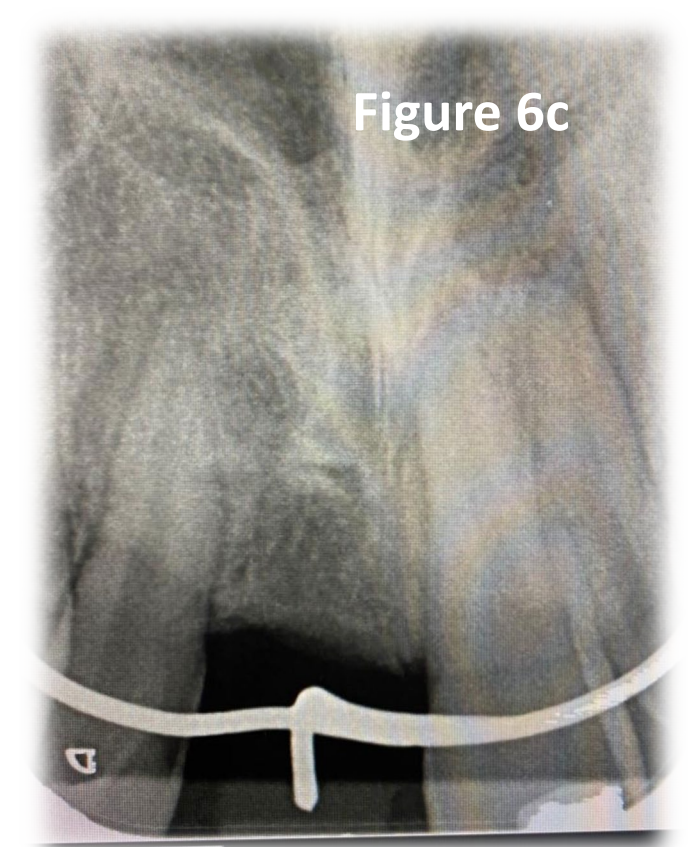


Figure 6c

CONCLUSION

- The expected alveolar ridge growth outcome was reached due to decoronation timing was adequate in growing patient in pubertal growth peak.
- During the follow-ups, growth of the alveolar ridge were noted clinically both in height and in width. We did not use quantitative 3D measurements of bone gain in this case.
- In addition to timing of the intervention, well-monitored and minimally invasive procedure technique and well-designed follow-ups may have been essential to prevent further complications and to maximize the benefits of the decoronation procedure. Thus, future studies should include 3D measurements either using a proper radiological technique or 3D digital impression during follow-ups.

REFERENCES

- Andreasen JO. Relationship between cell damage in the periodontal ligament after replantation and subsequent development of root resorption. Acta Odont Scand 1981; 39: 15-25.
- de Souza RF, Travess H, Newton T, Marchesan MA. Interventions for treating traumatised ankylosed permanent front teeth. Cochrane Database Syst Rev. 2015 Dec 16;2015(12).
- Malmgren B, Cvek M, Lundberg M, Frykholm A. Surgical treatment of ankylosed and infrapositioned reimplanted incisors in adolescents. Scand J Dent Res 1984; 92: 391-9.
- Malmgren B. Ridge preservation/decoronation. Pediatr Dent 2013; 35: 164-9.
- Mohadeb JVN, Somar M, He H. Effectiveness of decoronation technique in the treatment of ankylosis: A systematic review. Dent Traumatol 2016; 32: 255-63.
- Shay B, Mijiritsky E, Bronstein M, Govani-Levi M, Ben Simhon T, Chackartchi T. Flapless decoronation: A minimally invasive approach. Int J Environ Res Public Health 2022; 20: 603

Contact details of the authors

- Tseveenjav B: Adjunct professor & specialist in clinical/ pediatric dentistry
battsetseg.tseveenjav@helsinki.fi; battsetseg.tseveenjav@utu.fi
- Alapulli H: Depute Chief Dentist at Children's Hospital & specialist in clinical/ pediatric dentistry
heikki.alapulli@hus.fi